

EP CASE REPORT

The use of a lumenless tip-fixation lead in coronary vein

Tsz Kin Tam^{1*}, Sze Man Fiona Yuen², Chin Pang Gary Chan¹, and Yat Sun Joseph Chan¹

¹Department of Medicine and Therapeutics, Prince of Wales Hospital, 30-32 Ngan Shing Street, Shatin, NT, Hong Kong; and ²Department of Medicine and Therapeutics, North District Hospital, Hong Kong

* Corresponding author. Tel: (852) 35051459; fax: (852) 26373852. E-mail address: drtamtszkin@gmail.com

Case presentation

A 78-year-old female patient had history of chronic rheumatic heart disease and symptomatic sick sinus syndrome. She was treated with mechanical mitral and tricuspid valve replacement with epicardial pacemaker implantation in year 2003. Epicardial pacemaker generator change was performed in year 2012. There was gradual increase in left ventricular (LV) lead threshold to 3.0 V/0.52 ms. Second pacemaker generator change was attempted in year 2017 but was complicated with significant wound haematoma formation. Eventually removal of epicardial generator was required. The epicardial leads were capped off.

Patient declined epicardial lead revision given the risk associated with pericardial access with the expected adhesion following surgery. We proceeded for transvenous pacing through branches of coronary sinus (CS). Unfortunately, balloon occlusive venogram showed absence of posterolateral branch of adequate size to accommodate pacing lead (Figure 1A). A bipolar LV lead with circumferential fixation feature (Attain Stability 20066, Medtronic Inc.) was placed at several positions in the septal branches (Figure 1B); however, there was no capture at all the sites tested at the highest output. We then attempted His-bundle pacing (SelectSecure model 3830, Medtronic Inc.) supported with delivery sheath (C315His, Medtronic Inc.). However, owing to the large right atrium size (max 8.1 cm length on computer tomography), we were unable to position the pacing lead near the His-bundle region to achieve direct or indirect His-bundle pacing. After

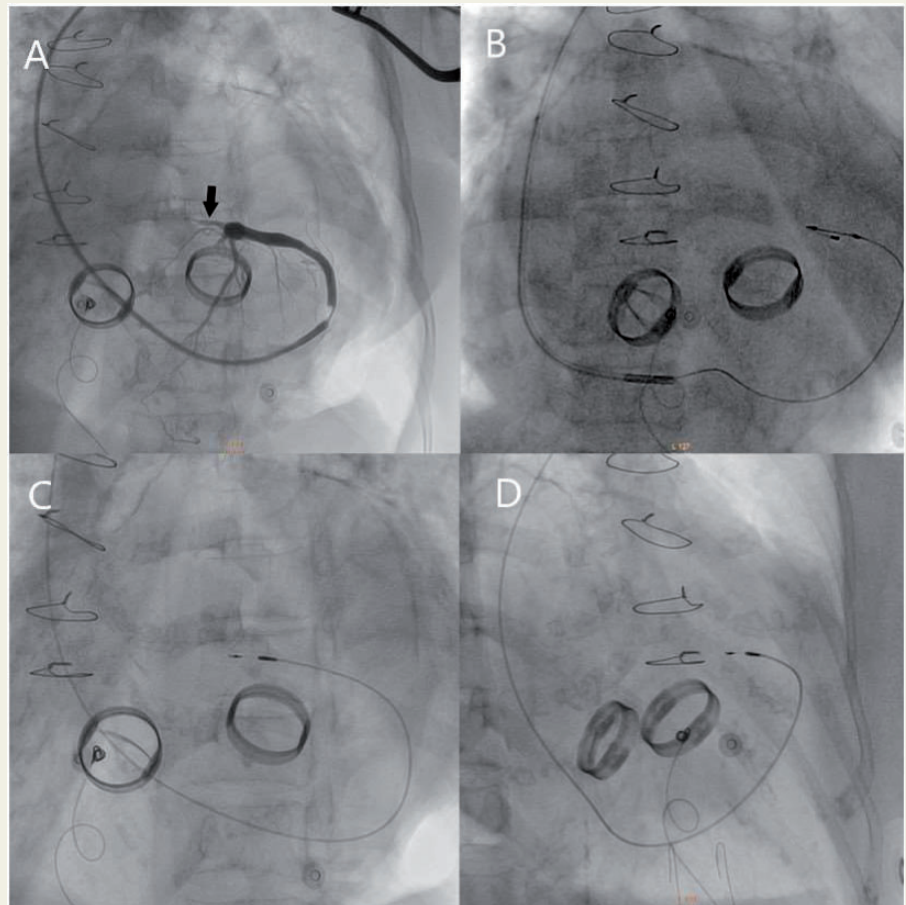


Figure 1 (A) Balloon occlusive coronary venogram. Arrow points to the final lead position where good parameters were obtained. (B) One of the attempts of coronary vein lead placement with conventional LV lead failing to capture. (C and D) left anterior oblique and right anterior oblique view of final lead position of the tip-fixation lead. LV, left ventricular.

After

exhausted the above options, LV pacing was reattempted with a tip-fixation lead (SelectSecure model 3830, Medtronic Inc.) via a subselector delivery sheath (Figure 1C,D). Before screwing-in, there was again no capture despite maximal output. We then aim the lead towards the myocardial side and deploy the tip-fixation screw. We were able to achieve satisfactory pacing parameters (impedance 1082 Ω , R wave 5.6–8.0 mV, and threshold 1.25 V/0.40 ms). There was no pericardial effusion on post-procedural echocardiogram. The pacing and sensing parameters remained stable at follow-up.

Discussion

In patient with mechanical tricuspid valve, right ventricular lead placement is contraindicated. Surgical epicardial lead placement was anticipated to be challenging given pericardial adhesion. Left ventricular pacing with conventional coronary vein lead¹ and His-bundle pacing² are generally feasible. Another option would be LV endocardial pacing via transseptal route which is contraindicated in this case because of the presence of mechanical mitral prosthesis.

As the above pacing strategies failed, we attempted use of SelectSecure lead in the coronary vein. Conventionally, this lumenless tip-fixation lead was used for pacing paediatric patients with congenital heart disease,³ or His-bundle pacing. Comparing to conventional CS lead which adopts circumferential fixation, the tip screw of SelectSecure is directly embedded into viable myocardium which could explain its superior pacing efficacy in this case. Pericardial effusion is a potential complication, but arguably can be minimized if the lead is screwed to a small branch of coronary vein and necessary precautions are taken to ensure the screw pointing towards the myocardial side.

In conclusion, in cases with mechanical tricuspid valve where conventional circumferential fixation coronary vein lead fails to capture, a tip-fixation lead can be a feasible alternative.

Conflict of interest: none declared.

References

1. Sideris S, Drakopoulou M, Oikonomopoulos G, Gatzoulis K, Stavropoulos G, Limperiadis D *et al.* Left ventricular pacing through coronary sinus is feasible and safe for patients with prior tricuspid valve intervention. *Pacing Clin Electrophysiol* 2016;**39**:378–81.
2. Sharma P, Subzposh F, Ellenbogen K, Vijayaraman P. Permanent His-bundle pacing in patients with prosthetic cardiac valves. *Heart Rhythm* 2017;**14**:59–64.
3. Cantù F, De Filippo P, Gabbarini F, Borghi A, Brambilla R, Ferrero P *et al.* Selective-site pacing in paediatric patients: a new application of the Select Secure system. *Europace* 2009;**11**:601–6.